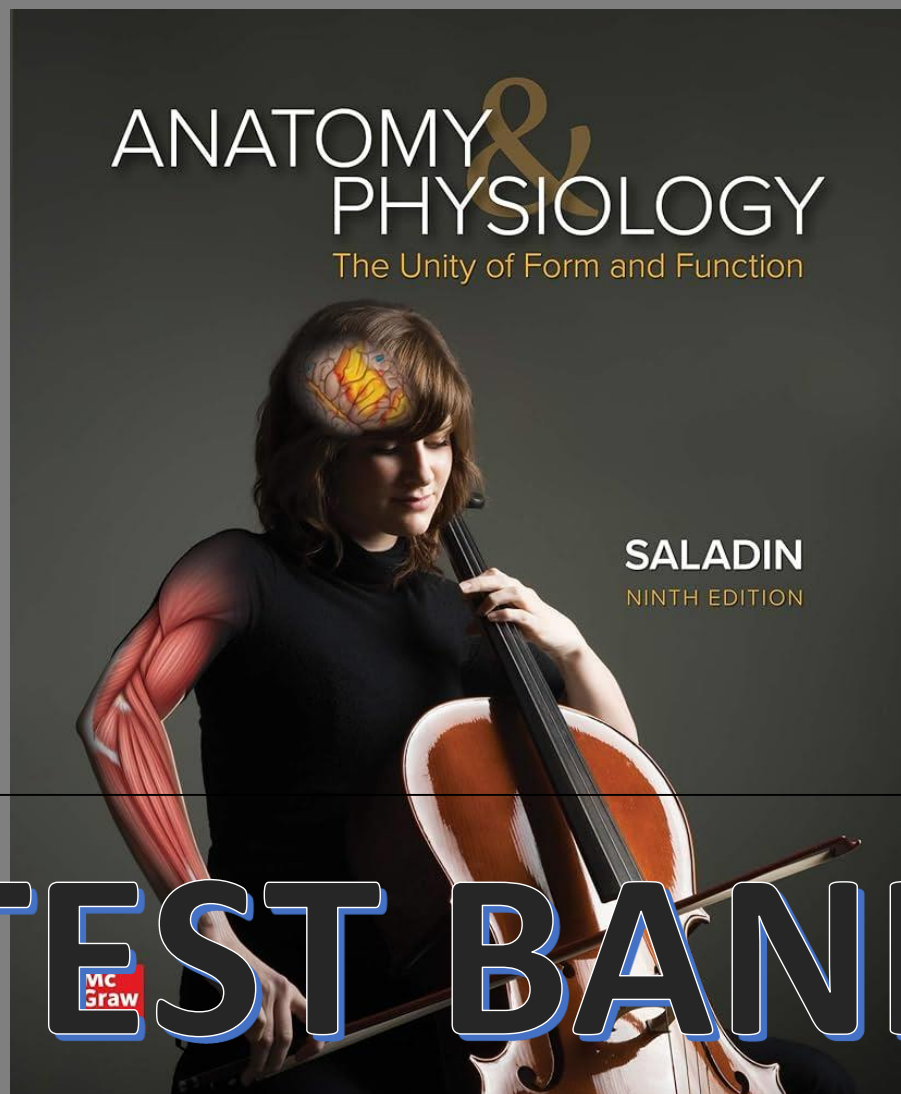


TEST BANK

Anatomy and Physiology The Unity of
Form and Function 9th Edition by
Kenneth Saladin



TEST BANK

Test Bank for Anatomy & Physiology: The Unity of Form and Function, 9th Edition By Kenneth Saladin

Table of Content

Part One Organization of the Body
1 Major Themes of Anatomy and Physiology
ATLAS A General Orientation to Human Anatomy
2 The Chemistry of Life
3 Cellular Form and Function
4 Genes and Cellular Function
5 The Human Tissues
Part Two Support and Movement
6 The Integumentary System
7 Bone Tissue
8 The Skeletal System
9 Joints
10 The Muscular System
ATLAS B Regional and Surface Anatomy
11 Muscular Tissue
Part Three Internal Coordination and Control
12 Nervous Tissue
13 The Spinal Cord, Spinal Nerves, and Somatic Reflexes
14 The Brain and Cranial Nerves
15 The Autonomic Nervous System and Visceral Reflexes
16 Sense Organs
17 The Endocrine System
Part Four Circulation and Defense
18 The Circulatory System: Blood
19 The Circulatory System: Heart
20 The Circulatory System: Blood Vessels and Circulation
21 The Lymphatic and Immune Systems
Part Five Intake and Output
22 The Respiratory System
23 The Urinary System
24 Fluid, Electrolyte, and Acid - Base Balance
25 The Digestive System
26 Nutrition and Metabolism
Part Six Reproduction and the Life Cycle
27 The Male Reproductive System
28 The Female Reproductive System
29 Human Development and Aging

ATLAS A

TRUE/FALSE - Write 'T' if the statement is true and 'F' if the statement is false.

1) The frontal plane passes vertically through the body or an organ and divides it into equal right and left portions.

- true
- false

2) The cut of a guillotine (decapitation) is an example of a section done in the midsagittal plane.

- true
- false

3) The appendicular region consists of the head, neck, and trunk.

- true
- false

4) The appendix is typically found in the right lower quadrant.

- true
- false

5) The liver is proximal to the diaphragm.

- true
- false

6) When the abdomen is divided into nine regions, the most superior horizontal line is called the midclavicular line.

- true
- false

7) The most lateral and superior region of the abdomen is called the hypochondriac region.

- true
- false

8) The heart occupies a space called the pericardial cavity between the parietal and visceral pericardium.

- true
- false

9) The cranial cavity contains the brain.

- true
- false

MULTIPLE CHOICE - Choose the one alternative that best completes the statement or answers the question.

10) The _____ cavity is inferior to the _____ cavity.

- A) cranial; thoracic
- B) thoracic; abdominopelvic
- C) pericardial; pleural
- D) thoracic; peritoneal
- E) thoracic; cranial

11) The most superior segment of the upper limb is called the _____.

- A) digits
- B) manual region
- C) carpal region
- D) antebrachial region
- E) brachial region

12) The _____ region of the left lower limb is proximal to the _____ region of the ipsilateral limb.

- A) carpal; manual
- B) femoral; crural
- C) antebrachial; brachial
- D) tarsal; crural
- E) brachial; femoral

13) The _____ wraps around the stomach, small intestine, and parts of the large intestine.

- A) pleura
- B) pericardium
- C) meninges
- D) visceral peritoneum
- E) parietal peritoneum

14) The _____ is an organ directly associated with the _____ and _____ systems.

- A) stomach; digestive; reproductive
- B) pancreas; digestive; endocrine
- C) small intestine; digestive; integumentary
- D) testis; male reproductive; urinary
- E) ovary; female reproductive; lymphatic

15) Which one of the following is *not* in the correct anatomical position?

- A) Arms at sides
- B) Standing upright
- C) Face and eyes facing forward
- D) Feet flat on the floor
- E) Palms facing hips

16) The plane that passes vertically through the body or an organ and divides it into anterior and posterior portions is called the _____ plane.

- A) sagittal
- B) frontal
- C) median
- D) transverse
- E) oblique

17) The interscapular region is _____ to the scapular region.

- A) anterior
- B) posterior
- C) medial
- D) lateral
- E) superior

18) The sternum (breastbone) is _____ to the vertebral column.

- A) anterior
- B) posterior
- C) superior
- D) inferior
- E) medial

- 19) The _____ part of the small intestine is the part closest to the stomach.
- A) dorsal
 - B) ventral
 - C) proximal
 - D) distal
 - E) medial
- 20) The right shoulder is _____ and _____ to the umbilical region.
- A) superior; lateral
 - B) superior; medial
 - C) inferior; lateral
 - D) inferior; medial
 - E) posterior; lateral
- 21) The trachea is _____ to the esophagus.
- A) superior
 - B) dorsal
 - C) anterior
 - D) posterior
 - E) inferior
- 22) In the cat, the head is _____ to the tail. In the human, the head is _____ to the gluteal region (buttock).
- A) superior; superior
 - B) anterior; superior
 - C) posterior; dorsal
 - D) ventral; distal
 - E) anterior; posterior